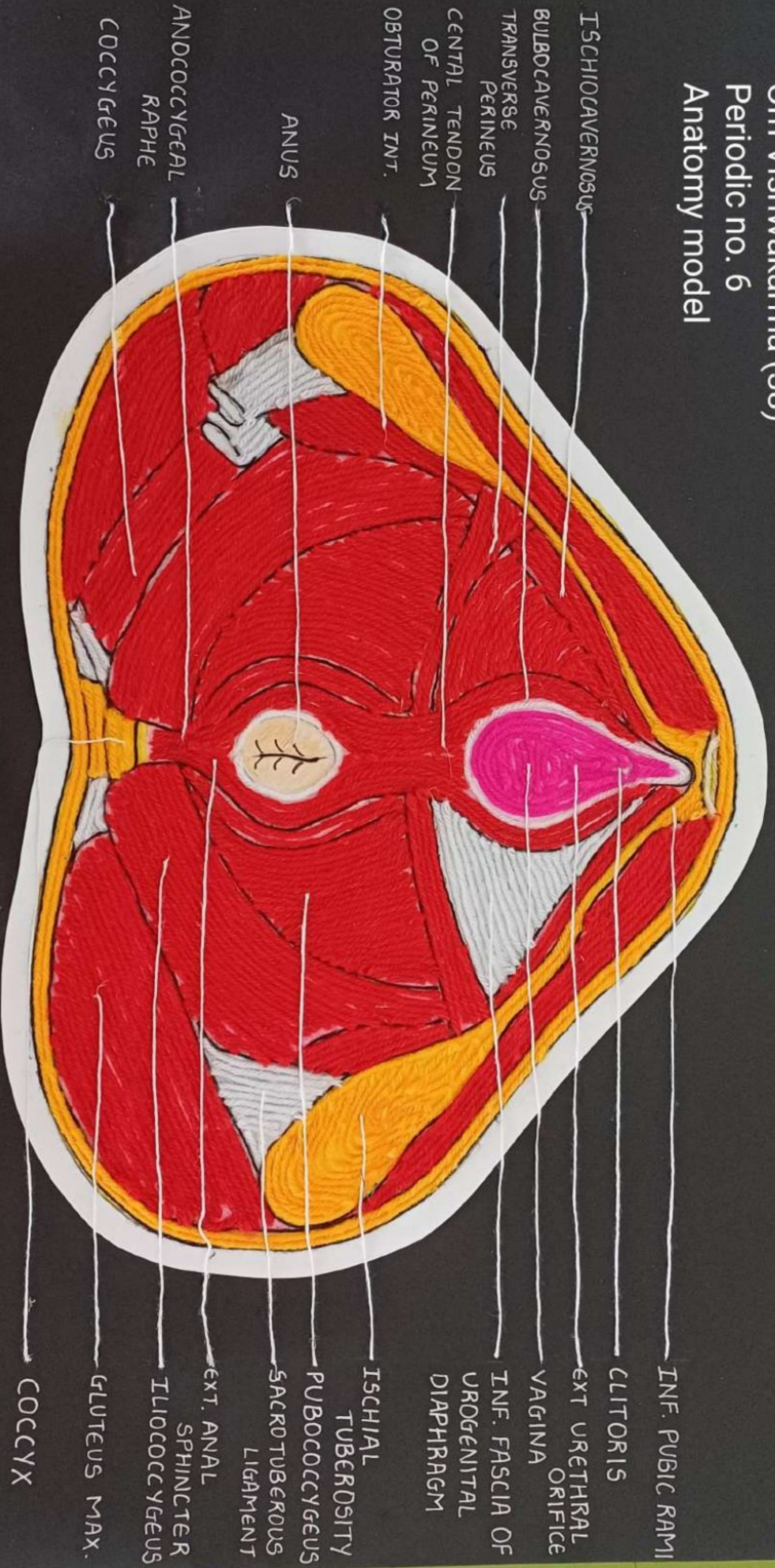


Muscles of the Pelvic Floor - Female perineum

Name : Shruti Verma(37) &
Om Vishwakarma (38)
Periodic no. 6
Anatomy model



ISCHIOCAVERNOSUS
BULBOCAVERNOSUS
TRANSVERSE PERINEUS
CENTRAL TENDON OF PERINEUM
OBTURATOR INT.
ANUS
ANDOCOCCYGEAL RAPHE
COCCYGEUS

INF. PUBIC RAMI
CLITORIS
EXT URETHRAL ORIFICE
VAGINA
INF. FASCIA OF UROGENITAL DIAPHRAGM

ISCHIAL TUBEROSITY
PUBOCOCCYGEUS
SACRO TUBEROUS LIGAMENT
EXT. ANAL SPHINCTER
ILIOCOCCYGEUS
GLUTEUS MAX.
COCCYX

BY
-SHRUTI VERMA (37)
-OM VISHWAKARMA (38)